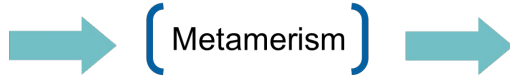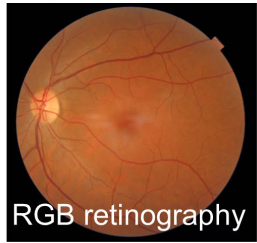


# Colorimetric analysis of eye fundus structures with multispectral retinography

Francisco J. Burgos-Fernández, Tommaso Alterini, Fernando Díaz-Doutón, Meritxell Vilaseca

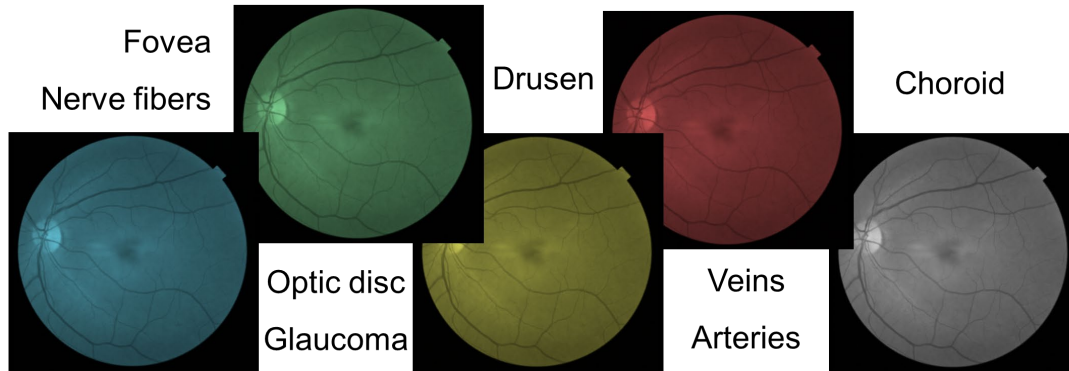
Centre for Sensors, Instruments and Systems Development,  
Universitat Politècnica de Catalunya (Terrassa, Spain)

## INTRODUCTION



Diagnosis limited: restricted discrimination of structures

Solution:  
**Multispectral imaging**

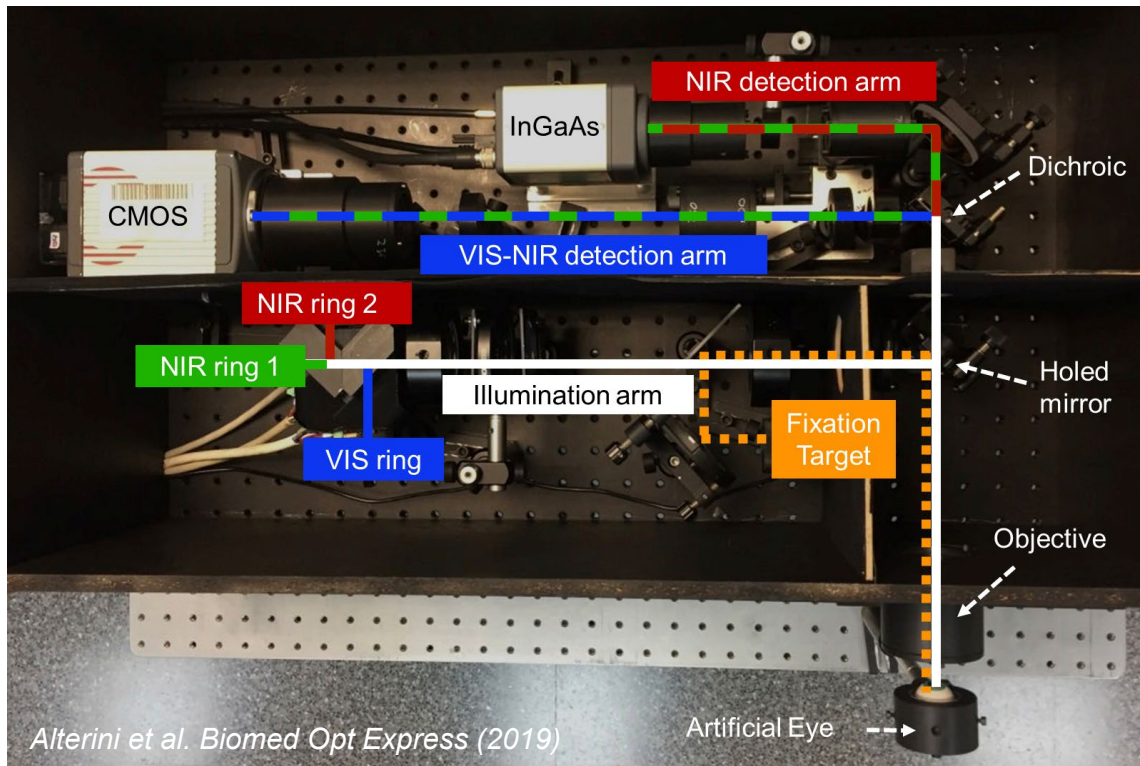


## GOAL

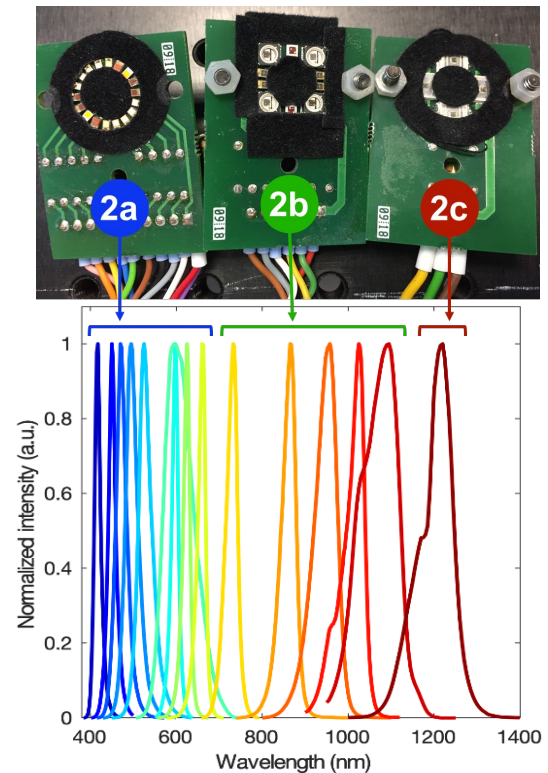
Study the **colorimetric and spectral features** of **eye fundus structures** in healthy and diseased subjects by means of a **fast visible and extended infrared multispectral fundus camera** (400 nm – 1300 nm) with high spectral and spatial resolution.

## MULTISPECTRAL FUNDUS CAMERA

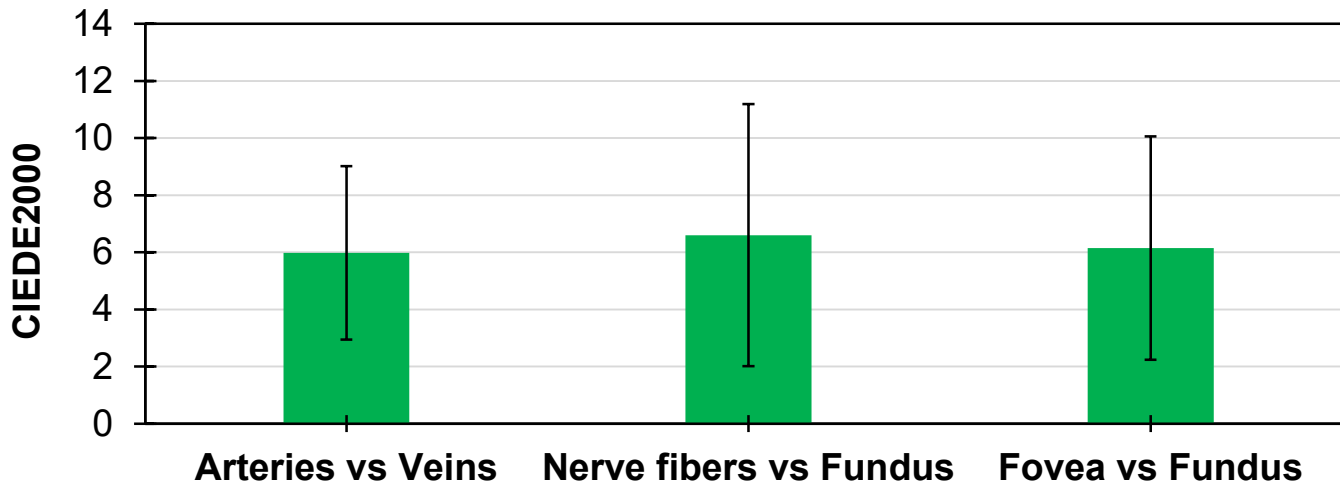
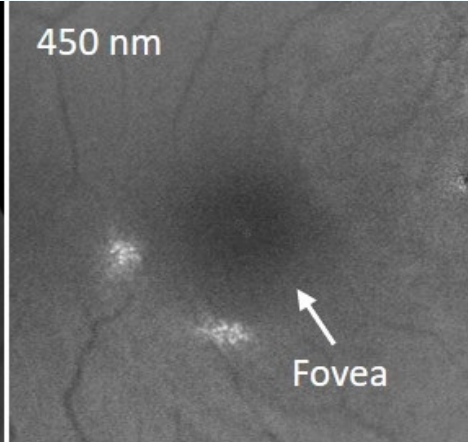
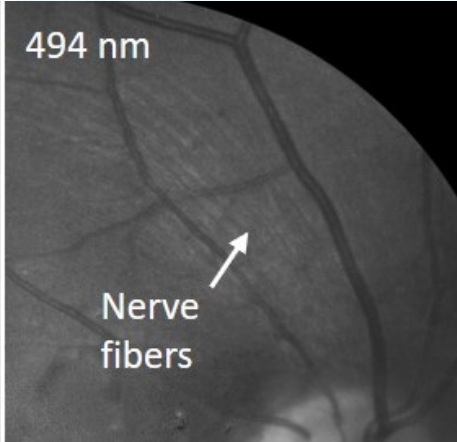
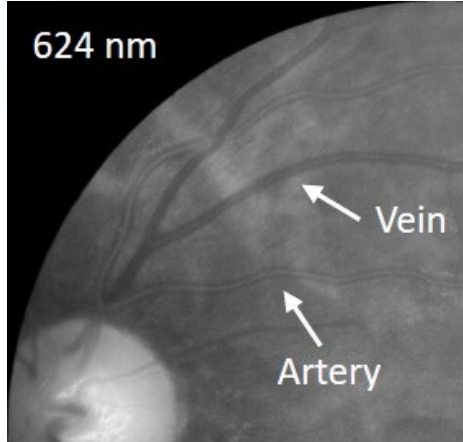
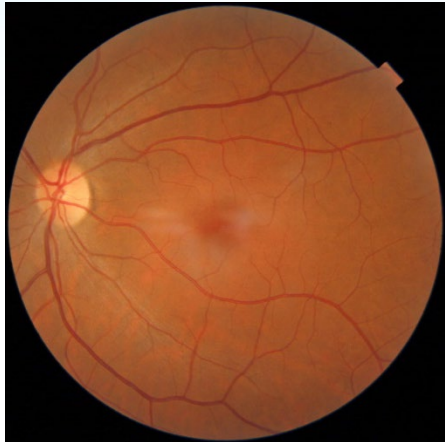### Setup



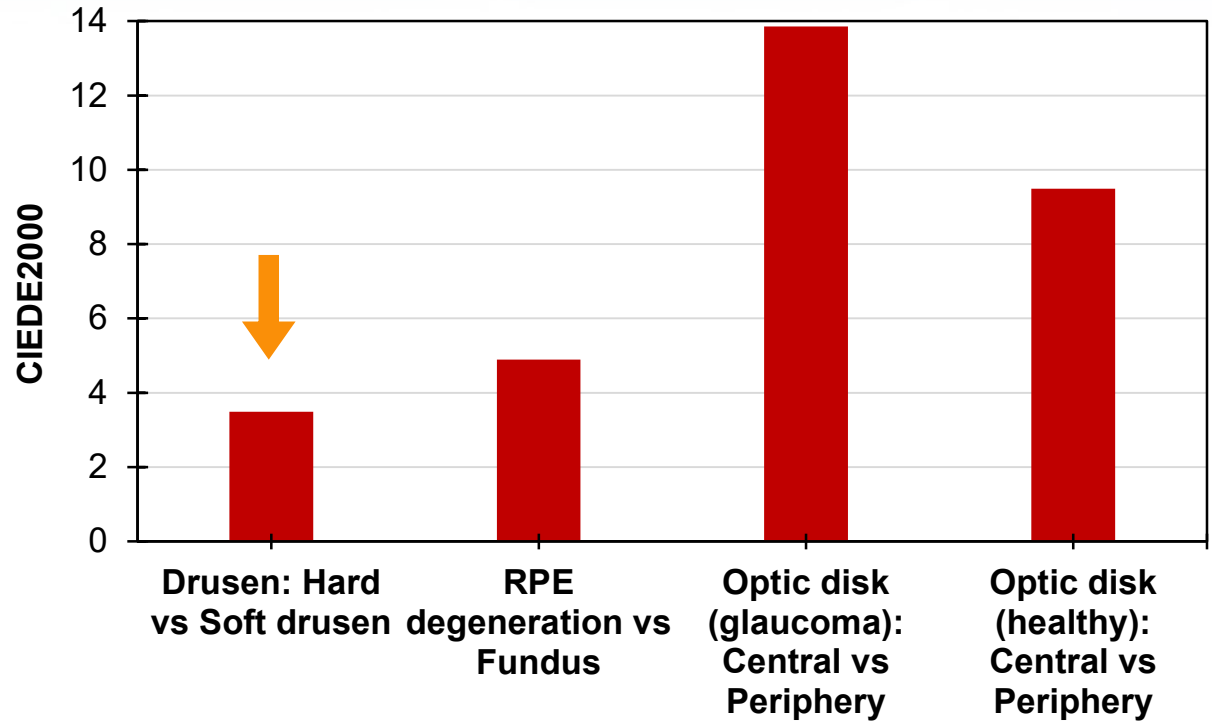
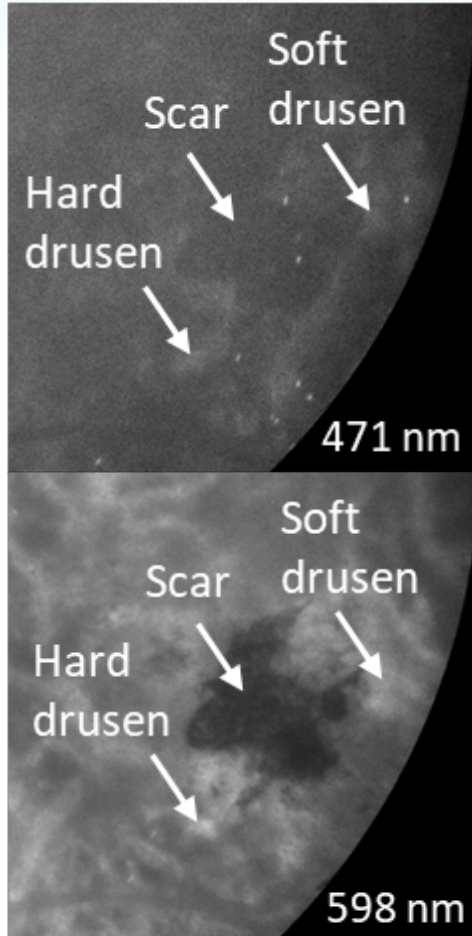
### Light source



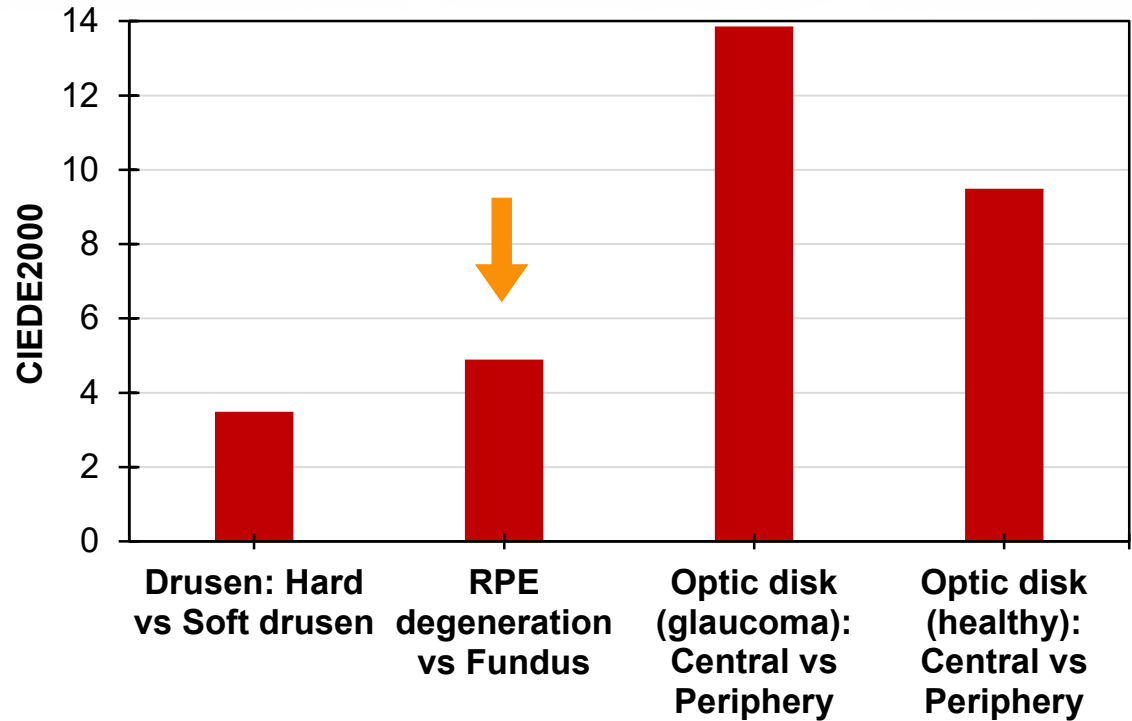
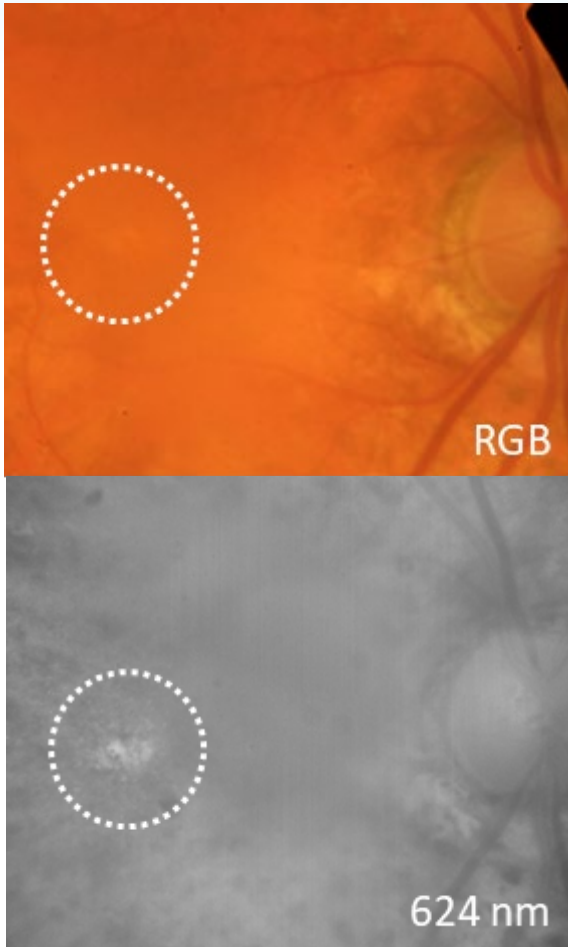
## RESULTS: Healthy



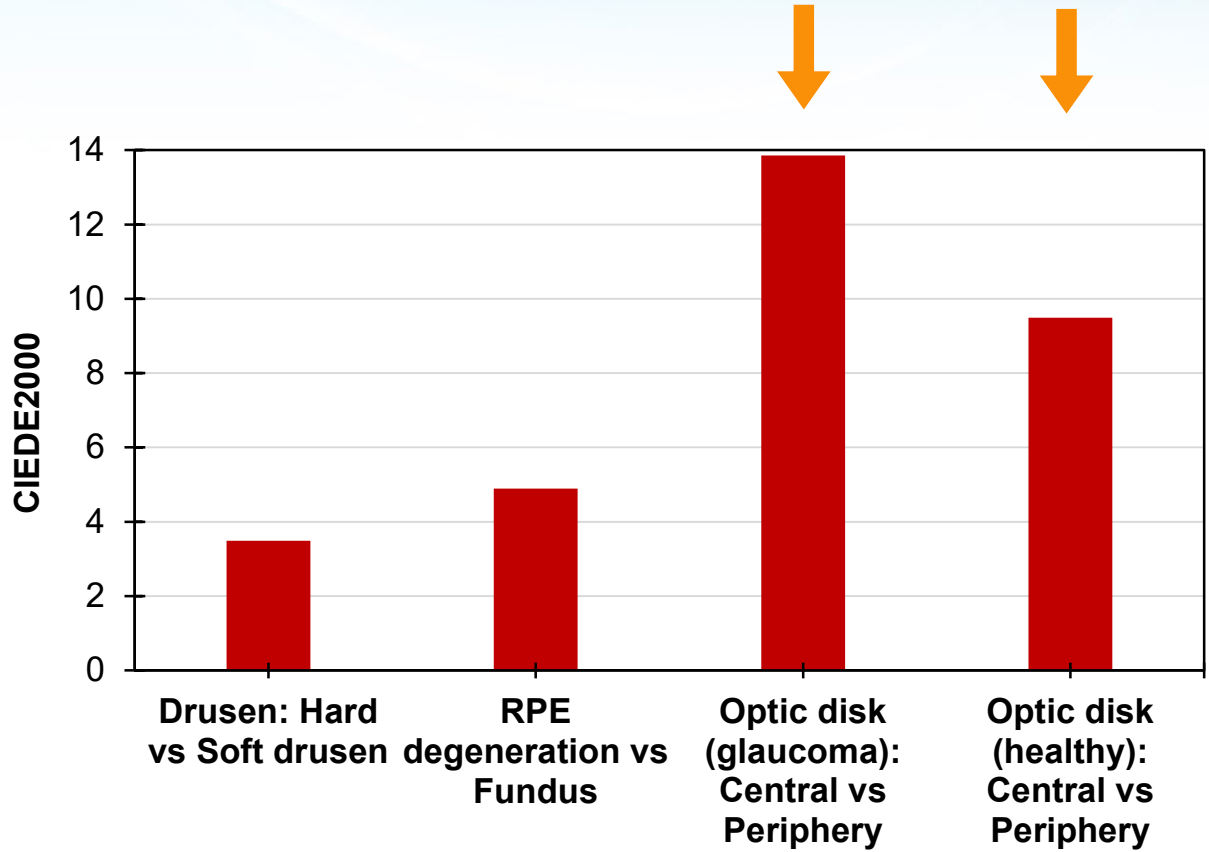
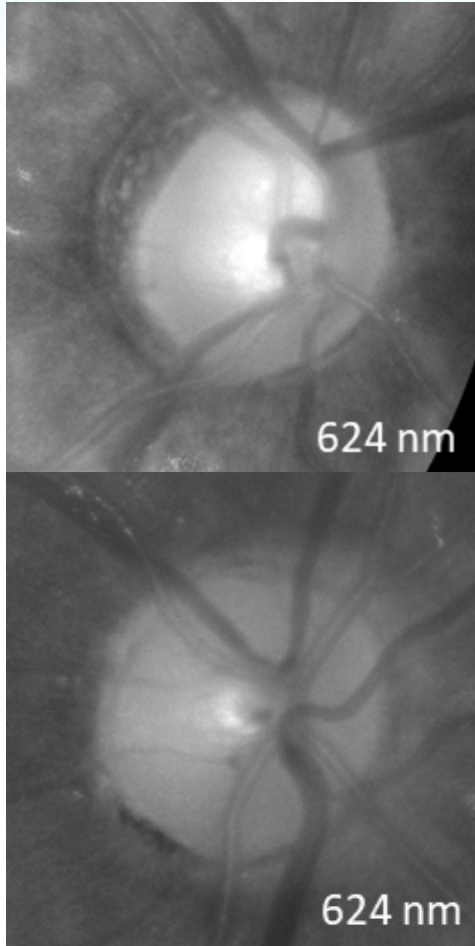
## RESULTS: Diseased. Age-related macular degen.



## RESULTS: **Diseased.** RPE degeneration



## RESULTS: Diseased. Glaucoma



## CONCLUSIONS

### Powerful diagnostic tool

Precise color evaluation from spectral reflectance instead of RGB data.

Early detection =  
Early treatment =  
Less/No vision loss

**CONTACT:** [francisco.javier.burgos@upc.edu](mailto:francisco.javier.burgos@upc.edu)